



RESEARCH ARTICLE

EXTRA ORAL MANDIBULAR THIRD MOLAR: A CASE REPORT

¹Dr. Mamatha, N.S., ²Dr. Satheesh Kumar and ³*Dr. Narahari Ranganatha

¹ Professor, Dept of Oral & Maxillofacial Surgery, Rajarajeswari Dental College & Hospital, RGUHS No. 14, Ramohalli Cross, Mysore Road, Kumbalgodu, Bangalore -560074

²NO 40, arunagiriyar street, tamil min nagar, thiruvannamalai. 606601 Tamil nadu

³Senior Lecturer, Dept of Oral & Maxillofacial Surgery, Rajarajeswari Dental College & Hospital, RGUHS No. 14, Ramohalli Cross, Mysore Road, Kumbalgodu, Bangalore 560074

ARTICLE INFO

Article History:

Received 24th December, 2016

Received in revised form

15th January, 2017

Accepted 24th February, 2017

Published online 31st March, 2017

Keywords:

Ectopic Eruption,
Third Molar,
Transcutaneous Fistula.

ABSTRACT

Ectopic eruption of tooth in the oral cavity is often seen. The eruption of teeth extra orally is an extremely rare phenomenon. We report a rare case of mandibular third molar erupting through transcutaneous sinus in a 70 year old patient. CBCT revealed mandibular third molar erupting lateral to the buccal cortex through extra oral sinus. A provisional diagnosis of infected mandibular third molar was made and removal was done through extra oral approach under local anesthesia. The patient recovery was uneventful.

INTRODUCTION

Tooth development occur from multistep interaction between the oral epithelium and the underlying mesenchymal tissue. This series of tissue interaction results in formation of 20 tooth germs for the primary dentition and 32 tooth germs for permanent dentition any disturbances in the tissue interaction during tooth development may lead to ectopic tooth development and eruption. Ectopic tooth means displaced away from its usual anatomic position (Martin *et al.*, 2012). In many cases the etiology cannot be identified. The presence of ectopic teeth is uncommon, and it is estimated to occur in 1% of general population (Nagarajappa, 2011).

The causes for ectopic eruption may be:

- Abnormal displacement of tooth bud in embryonic life, Long eruption pathway (Dash *et al.*, 2004),
- Obstruction of the eruption path due to: supernumerary teeth, odontomas, scar tissue, odontogenic tumors or cysts,
- Defects in the follicle or PDL due to trauma, surgery, congenital diseases or other causes (Andersson *et al.*, 2008),
- Endocrine disorders, infections, hereditary factors (Dash *et al.*, 2004).

*Corresponding author: Dr. Narahari Ranganatha,

³Senior Lecturer, Dept of Oral & Maxillofacial Surgery, Rajarajeswari Dental College & Hospital, RGUHS No. 14, Ramohalli Cross, Mysore Road, Kumbalgodu, Bangalore 560074.

Ectopic eruption of teeth in oral cavity are often seen, other sites of ectopic eruption are maxillary sinus, mandibular condyle, coronoid process, orbit, palate, chin, nasal cavity and oropharynx (Nagarajappa, 2011). The finding of an impacted mandibular third molar in an ectopic position, displaced away from its usual anatomic position is an infrequent event. Their heterotopic positions reported are in the lower border of the mandible, ascending ramus of the mandible, or in the condylar and coronoid process (Wang, 2008). They are not diagnosed routinely and done only when symptomatic (Katakol, 2014). Very few cases have been reported in the literature; therefore, the knowledge about its etiology, clinical features, therapeutic options, and surgical approaches for extraction is limited (Martin *et al.*, 2012). This is an interesting case report presenting extra oral eruption of mandibular third molar following infection and was treated by removal of the tooth by extra oral approach.

Case Report

A 70 year male presented to department of oral maxillofacial surgery with a complaint of pus drainage extra orally since one year. Patient gave a history of extra oral swelling on the right lower third of the face 1 year back, it ruptured and drained on its own. Following which slight pus discharge continued till date. His medical history was not significant. On examination there was an extra oral swelling with draining sinus on the right lower third of face measuring 0.5 x 0.5 cm, extending anteromedial 5cms from angle of mouth and 3cms from the ear lobe.

Superioinferiorly 3cm from the ala tragal line to the angle of mandible. Tooth like structure was seen at the site of extraoral sinus opening.

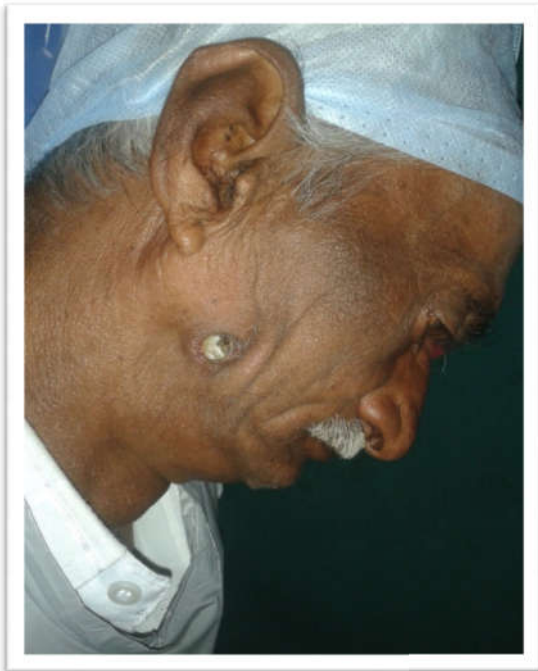


Figure 1. Extra oral view showing the crown of the ectopic tooth

On palpation inspectory findings were confirmed, slight pus extruded and it was non tender. Intra oral examination revealed edentulous upper and lower jaws. OPG revealed bilaterally impacted third molars. Right mandibular third molar was deeply impacted at the inferior border with a radiolucency around it (Class 3, Position C).

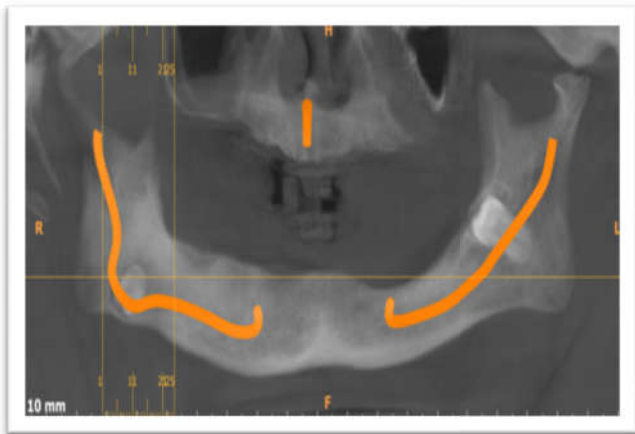


Figure 2. Panoramic view showing the presence of 48 the lower border of the mandible and 38 impacted

CBCT was taken crown of right mandibular third molar was buccal to buccal cortex roots with close relation to inferior alveolar nerve. Patient was diagnosed with an ectopic impaction of lower third molar on the right side and mesioangular impaction of lower third molar on left side. As the tooth was symptomatic on the right side, the decision was to remove the impacted ectopically placed mandibular third molar tooth under local anesthesia. Presence of a draining sinus extraorally and the position of the tooth favoured in choosing an extraoral procedure.

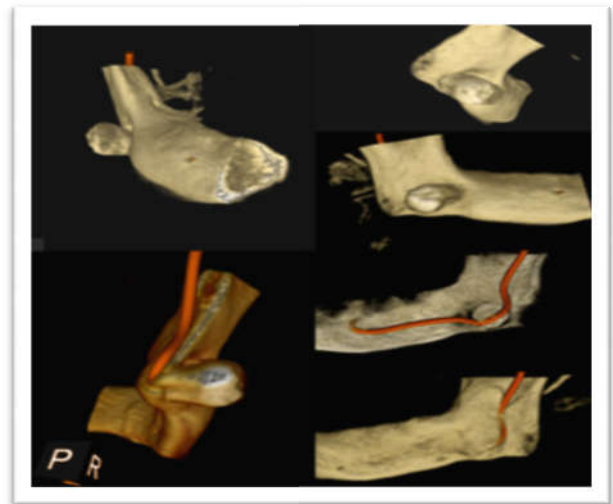


Figure 3. 3D CBCT showing buccally placed 48 and inferior dental canal is above the root and lingual

The patient was counselled and advised for extra oral surgical removal. Ectopic impaction was accessed through extraoral sinus, tooth was delivered as a whole, socket was curetted, the extra oral sinus margin was excised.

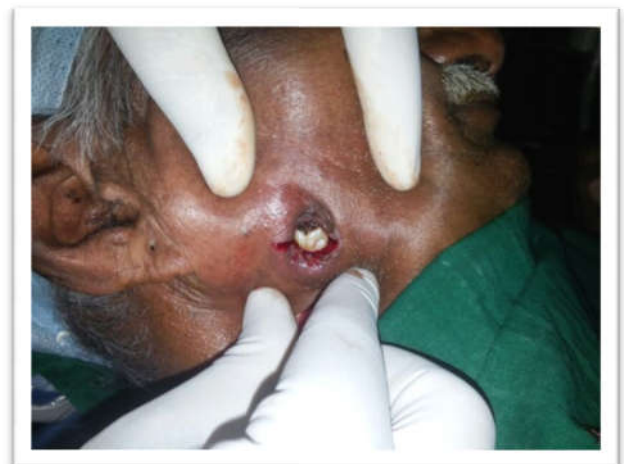


Figure 4. Intra operative view showing the incision

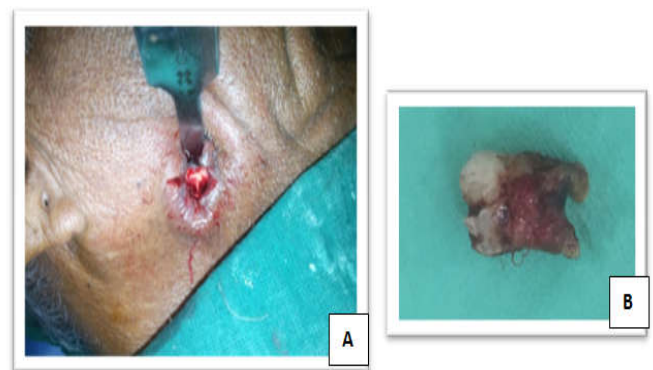


Figure 5. Intra operative view -post removal of the tooth (A) extracted tooth 48 with fully formed crown and roots (B)

The operative site was evaluated for any possible bleeder. After thorough wound toileting and achieving hemostasis, layered primary closure was done.

The patient received oral antibiotic, anti-inflammatory drugs. The patient was followed-up regularly, at the end of 1st month post-operatively healing was satisfactory.

DISCUSSION

The eruption of tooth extra orally is rare. The limited availability of literature, limits the scope of discussion about the ectopic mandibular third molars. The true incidence and number of cases of ectopically impacted mandibular third molars remains still unclear, mainly because of under reporting of cases. They are usually diagnosed when they become symptomatic (Katakol, 2014). The aetiology for ectopic eruption is not clear. In this case the ectopic tooth was found to have erupted extra orally following infection and radiographically it was inferior and buccal to the inferior dental nerve on right angle of the mandible. The ectopic tooth may be diagnosed during routine clinical or radiographic examination and may be asymptomatic. Investigations commonly used for the ectopic mandibular third molar are IOPAR, OPG and CBCT. In our case OPG revealed bilaterally impacted third molars in the edentulous jaw. Right mandibular third molar was deeply impacted at the inferior border with a radiolucency around it (Class 3, Position C).

There was diversion of the canal and interruption of the white line of the canal. Exact relationship of the inferior alveolar nerve to the root of the tooth was confirmed using CBCT, which showed the inferior alveolar nerve was lingual to root apex of the impacted tooth. CBCT is most commonly used due to better resolution of the images, less radiation exposure and cost effective than conventional CT scans. Pell and Gregory is the widely used classification for predicting the position and level of impacted mandibular third molar based on spatial relationship as revealed by the radiographs with the ramus and occlusal plane. Pell and Gregory classification is unreliable as predictor of difficulty in extracting impacted mandibular third molars and has little value in clinical practice (Shenoy *et al.*, 2014). In our case the tooth was located in class 3 position C and was ectopic. Impacted mandibular third molar classification by Naaj IA *et al.*, has classified in relation to the mandibular canal and suggested indication for the use of each surgical approach for its extraction.

In this operative third molar classification (TMC) TMC III refers to third molars that are completely localized below the mandibular canal. This study suggested TMC III were treated with the extra oral approach (Shenoy *et al.*, 2014). The severity of symptoms or the nature of the lesion associated with the tooth indicates the management of such teeth. Few cases have shown a spontaneous regression of symptoms without any treatment. This may be due to bone resorption, lining rupture and spontaneous decompression of cyst contents (Katakol, 2014). If the ectopic teeth is asymptomatic then periodic monitoring is required (Nagarajappa, 2011). Common indications for removal are acute inflammation, large lesions, prevention of infection and osteolysis/osteomyelitis, pathologic fracture/deformity of subcondylar region and patients with underlying systemic problems where serious consequences are expected. The method of management should be individualized and largely depends on the patient's and surgeon's preference.⁶ The removal of ectopic tooth requires careful planning based on location and position of tooth and morbidity associated with

surgery, an appropriate approach should be chosen which produces the least possible trauma to the patient (Nagarajappa, 2011). The risk of damaging the neuronal structures and the joint components, esthetic concerns, defect reconstruction after the surgery, and the age of the patient should be evaluated before treatment. The precise location of the ectopic tooth, sometimes with high resolution CT scans, may provide direction in choosing the appropriate surgical method (Wang, 2008). Surgical approaches to impacted mandibular third molar are three; they are intra or transoral, extraoral and endoscopically assisted. In transoral conventional either buccal or lingual approach or sometimes through sagittal split osteotomy procedure. Extra oral approach usually used either submandibular or preauricular depending on the location of the impacted tooth. In endoscopically assisted techniques fiber optic technology used with endoscope for the surgical removal. Intra oral approach is the most common approach for the impacted mandibular third molar. Advantageous with this approach is aesthetically good without any extra oral scar. However, in case of deeply impacted teeth there is increased risk of damage to inferior alveolar nerve, significant alveolar bone loss and risk of damaging the adjacent teeth. Intra oral sagittal split osteotomy is introduced to overcome the extensive removal of alveolar bone. This approach allows direct visualisation and good exposure of the surgical site but incidence of post operative inferior alveolar nerve damage been reported (Shenoy *et al.*, 2014).

Alling *et al.* introduced two techniques which use intraoral approaches. One of them requires a sagittal split of the mandibular posterior body and ramus to provide surgical access to the ectopic tooth. The other technique is the removal of a plate of lateral cortical bone with a bur and a unibevel chisel to give access to the cancellous portions of the mandible (Wang, 2008). Endoscope assisted surgical approach may not be indicated in all cases because of its limitation, but it is more conservative and gives access to the surgical site which would otherwise be difficult to reach via conventional trans-oral approach. This gives good illumination, magnification of the surgical site, smaller scar and decreased risk of damage to the facial nerve (Shenoy *et al.*, 2014). Extra oral approach is used in cases where teeth placed high in the ramus, neck of the condyle, sigmoid notch or at the lower border of the mandible. This allows the good exposure, less amount of bone removal and gives three dimensional orientation of the impacted tooth which prevents inadvertent fracture of the mandible. However, there will be minimal external scar and risk to damage the facial nerve branches with this approach. The practice of extraoral approach to remove the impacted tooth is very rare. Going through the literature indications for this approaches given as:

- Deeply impacted tooth and its very close proximity to the ID canal (in this case), on the lower border or at a higher level at the neck of the condyle.
- Deeply impacted tooth with dilacerated and hypercementosed roots.
- In cases of severe trismus.
- Third Molar Classification (TMC) III like in our case (Shenoy *et al.*, 2014).

Right mandibular third molar in the present case was erupting extra orally with a draining sinus and panoramic and CBCT scans showed that tooth was placed below the mandibular canal.

So, extraoral approach was chosen for its removal, inferior alveolar nerve was just above the roots of the tooth traversing antero-posteriorly.

Conclusion

Ectopic mandibular third molars are rare and found because of the clinical symptoms or accidentally discovered on radiography. However, the occurrence of such impactions is probably under reported. The severity of symptoms or the nature of the lesion associated with the tooth indicates the management of such teeth. Few cases have shown a spontaneous regression of symptoms without any treatment. The removal of ectopic tooth requires careful planning based on location and position of tooth and morbidity associated with surgery, an appropriate approach should be chosen which produces the least possible trauma to the patient. The method of management should be individualized and largely depends on the patient's and surgeon's preference. It is mandatory to educate the patient regarding the extraoral approach for better completion of the procedure. A careful handling of inferior dental nerve and extraoral soft tissue and skin will inevitably recover absolutely without any morbidity.

REFERENCES

- Martin, F. I., Cossio, P. I., Carranza, E.T., Golczer, V. E. P., Garcia, A. G. P. 2012. *Med Oral Patol Oral Cir Bucal*. 17 (6):e1013-7.
- Dash, J. K., Mohapatra, M., Mishra, L. 2004. Extraoral inverted teeth eruption: A case report. *Oral Surg Oral Med Oral Pathol Oral Radiol Endod.*, 98:37-9.
- Andersson, L., Khanberg, K. E., Pogrel, M. 2010. Oral and maxillofacial surgery; Wiley- Blackwell, 1st edition.
- Wang, C. et. al. 2008. Ectopic mandibular third molar in the ramus region: report of a case and literature review. *Oral Surg Oral Med Oral Pathol Oral Radiol Endod.*, 105:155-61.
- Katakol, B. 2014. Ectopic impaction of mandibular third molars. *Journal of Cranio-Maxillary Diseases* 3 (1).
- Shenoy, V. K., Priya, V., Kannadasan, K., Kengagsubbiah, S., Kumar, S. 2014. Extra-oral approach for removal of ectopic impacted lower third molar : A case report. *Journal of Clinical and Diagnostic Research*. 8 (11) : 27-28.
- Nagarajappa, D., Manjunatha, B.S. 2011. Sep-Dec, *J Oral Maxillofac Pathol*. 15(3):346-347.
