




ISSN : 2350-0743



RESEARCH ARTICLE

FIRST-TRIMESTER CYSTIC HYGROMA: PRENATAL DIAGNOSIS AND FETAL OUTCOME

Imen Ben Farhat, *Dhekra Toumi, Hela Mtir, OlfaZoukar and Raja Faleh

Department of Obstetrics and Gynecology, Maternity and Neonatology Center of Monastir, Monastir, Tunisia

ARTICLE INFO

Article History

Received 10th April, 2024

Received in revised form

16th May, 2024

Accepted 17th June, 2024

Published online 30th July, 2024

Keywords:

Cystic Hygroma; Chromosomal Disorders; Prenatal Diagnosis, Nuchal Translucency, Karyotype Abnormalities.

ABSTRACT

Cystic hygroma is a congenital lymphatic malformation frequently diagnosed during first-trimester ultrasound screenings. This anomaly, characterized by cystic masses typically found in the cervical and thoracic regions, poses significant challenges due to its association with chromosomal abnormalities, notably trisomy 21. We present a case study of a 32-year-old primigravida at 11 weeks of gestation diagnosed with a cervico-thoracic cystic hygroma measuring 4.5 mm in nuchal thickness, confirmed by Doppler ultrasound. Karyotyping revealed trisomy 21, prompting the decision for fetal termination. Discussion focuses on the clinical implications of cystic hygroma, emphasizing its poor perinatal prognosis and the importance of early detection and cytogenetic analysis in managing pregnancies affected by this condition. Understanding the ultrasound characteristics and prognostic factors associated with cystic hygroma is crucial for appropriate prenatal counseling and management strategies.

*Corresponding author: Dhekra Toumi

Copyright©2024, Imen Ben Farhat et al. This is an open access article distributed under the Creative Commons Attribution License, which permits unrestricted use, distribution, and reproduction in any medium, provided the original work is properly cited.

Citation: Imen Ben Farhat, Dhekra Toumi, Hela Mtir, OlfaZoukar and Raja Faleh. 2024. "First-trimester cystic hygroma: Prenatal diagnosis and fetal outcome.", International Journal of Recent Advances in Multidisciplinary Research, 11, (07), 10114-10116.

INTRODUCTION

First-trimester fetal ultrasound offers numerous clinical advantages. It not only accurately dates conception and identifies multiple pregnancies but also plays a crucial role in early detection of major fetal anomalies (1). One significant advancement is the detailed morphological study of the fetal nuchal region towards the end of the first trimester, particularly due to its established association with fetal chromosomal anomalies such as cervical hygroma and nuchal translucency. Fetal cystic hygromas are congenital cystic lymphatic malformations found solitarily or multiply within the retro and latero-cervical regions, with a prevalence estimated around 2% during first-trimester ultrasounds (2). This condition is believed to arise from a connection failure between the lymphatic system and jugular veins, leading to sacral lymphatic dilation and jugular lymphatic obstruction. It is often associated with a grim prognosis, characterized by a notable risk of aneuploidy, cardiac malformations, and perinatal death, compared to other manifestations like nuchal translucency.

Observation: Patient X, a 32-year-old primigravida at 11 weeks of gestation, presented with a diagnosis of cervico-thoracic cystic hygroma on first-trimester ultrasound. The ultrasound revealed a posterior cephalo-cervical cystic mass measuring 4.5 mm in thickness, with a thin avascular wall on Doppler, containing anechoic fluid. It was associated with dilation of jugular lymphatic sacs (Figure 1). Karyotyping confirmed trisomy 21. Upon agreement with the couple, the decision was made for fetal termination (Figure 2).

DISCUSSION

Cystic hygroma is a lymphatic malformation diagnosed during first-trimester pregnancy ultrasound, often associated with craniothoracic skin thickening (3). The definition of cystic hygroma on ultrasound varies in the literature, with some requiring sagittal septations while others do not. It is the most common fetal anomaly detected in the occipitocervical region (4). With the implementation of nuchal translucency assessment in first-trimester screening for aneuploidy, its detection rate has increased. The incidence varies between 1:285 to 1:1000 in different studies (5).

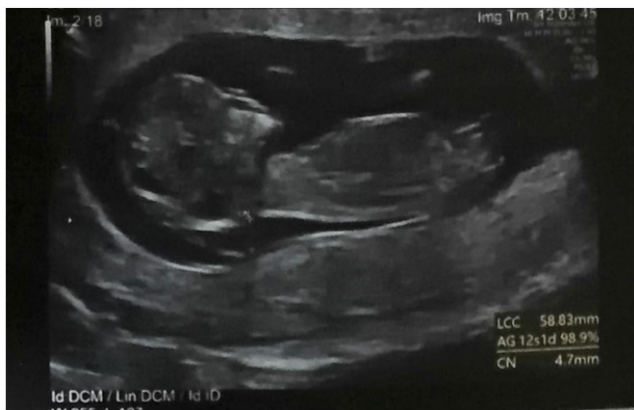

Figure 1. Ultrasonographic Appearance of Cervical Cystic Hygroma with 4.5 mm Nuchal Thickness

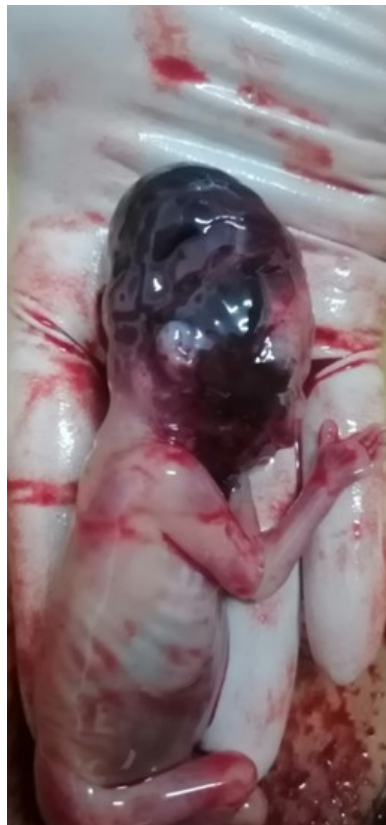

Figure 2. Macroscopic Appearance of a Fetus with Cystic Hygroma

Prenatal ultrasound diagnosis relies on demonstrating a septated or non-septated bilateral cystic lesion in the fetal occipitocervical region in both sagittal and axial planes. Aneuploidy, notably trisomy 21, trisomy 18, and Turner syndrome, are the most common chromosomal abnormalities associated with first-trimester cystic hygroma. Aneuploidy occurs more frequently in septated cases, ranging from 29% to 65% of affected fetuses in different studies.(6),(7). Cystic hygroma is associated with a very poor perinatal prognosis. Scholl and Durfee (2012) demonstrated that neck thickness correlates strictly with the risk of an unfavorable prognosis: each 1 mm increase in cystic hygroma thickness increases the risk of chromosomal abnormalities by 44%, congenital anomalies by 26%, fetal demise, intrauterine fetal death, or neonatal death by 47%, and overall unfavorable prognosis by 77% (8).

Despite normal karyotype in 41% of cases, severe cases with hydrops and polysyndromes may occur. Oligohydramnios is often described, and the placenta may be normal or thickened (hydrops). (9). Anasarca is also frequently found in 45% of cases on average (33% to 75%) and associated with a very poor prognosis (10). The timing of detection affects the outcome of cystic hygroma, with worse outcomes when detected in the first trimester compared to later in pregnancy. Malone et al. demonstrated a strong association between first-trimester cystic hygroma and aneuploidy(11). The presence of associated structural anomalies further worsens pregnancy outcomes, necessitating thorough structural evaluation, follow-up, and cytogenetic analysis for prognosis determination. Fetal hydrops development signifies a poor prognosis, regardless of other structural anomalies, often diagnosed later in the second trimester, thus requiring ongoing follow-up. Microarray analysis, utilized since 2013, can detect submicroscopic deletions and provide detailed information on deletions or duplications. De Wit et al. demonstrated that 3.1% to 7.9% of fetuses with structural anomalies and normal karyotype exhibit submicroscopic copy number variants (CNVs), highlighting its diagnostic and prognostic significance (12).

CONCLUSION

The diagnosis of cystic hygroma is primarily ultrasound-based and typically occurs during second-trimester obstetric ultrasound screening. However, karyotype analysis is essential, as rare cases of spontaneous resolution have been observed with a normal karyotype, although fetal prognosis remains poor.

Declaration of interest: The authors report no conflict of interest.

REFERENCES

1. Gynécologie Obstétrique & Fertilité 33 (2005) 750–754 G. Ducarme et al
2. Souradi H, Amqrane F, Bennani Z, Hijji M, Youssfi M, Bargach S. Hygroma kystique découvert à l'échographie du 1er trimestre : A propos de 03 cas. Int J Innov ApplStud. 2021; 34:414-9.
3. Lajeunesse C, Stadler A, Trombert B, Varlet MN, Patural H, Prieur F, Chene G. Hygroma kystique découvert à l'échographie obstétricale du 1er trimestre: caractéristiques échographiques, caryotypiques et devenir de la grossesse. J GynecolObstet Biol Reprod. 2014;43:455-62.
4. Graesslin O, Derniaux E, Alanio E, Vitry F, Que C. Characteristics and outcome of fetal cystic hygroma diagnosed in the first trimester. Acta ObstetGynecol2007;86:1442–1446. (4) Noia G, Pellegrino M, Masini L, Visconti D, Manzoni C, Chiaradia G, Caruso A. Fetal cystic hygroma: the importance of natural history. Eur J ObstetGynecolReprod Biol 2013;170:407–13
5. Gezdirici A, Ekiz A, Güleç EY, Kaya B, Sezer S, Atış Aydın A. How necessary is to analyze PTPN11 gene in fetuses with first trimester cystic hygroma and normal karyotype? J Matern Neonatal Med 2017;30:938–941.
6. Kharrat R, Yamamoto M, Roume J, Couderc S, Vialard F, Hillion Y, Ville Y. Karyotype and outcome of fetuses diagnosed with cystic hygroma in the first trimester in

- relation to nuchal translucency thickness. *PrenatDiagn*2006;26:369–372.
7. Schreurs L, Lannoo L, De Catte L, Van Schoubroeck D, Devriendt K, Richter J. First trimester cystic hygroma colli: Retrospective analysis in a tertiary center. *Eur J ObstetGynecolReprod Biol.* 2018 Dec;231:60-64. doi: 10.1016/j.ejogrb.2018.10.019. Epub 2018 Oct 9. PMID: 30321790.
 8. Scholl J, Durfee SM, Russell MA, Heard AJ, Ecker J, Panda B, Tanner C, Wolfberg A. First-Trimester Cystic Hygroma : Relationship of Nuchal Translucency Thickness and Outcomes. *ObstetGynecol*2012;120:7–13.
 9. Fouedjio JH, Fouelifack FY, Ebune LJ. Antenatal diagnosis and management of nuchal cystic hygroma: A case report in the Yaounde Central Maternity, Cameroon. *Clin Mother Child Health.* 2011;8
 10. Brambati B, Cislighi C, Tului L, Alberti E, Amidani M, Colombo U, et al. First trimester Down's syndrome screening using nuchal translucency: a prospective study in patients undergoing chorionic villus sampling. *Ultrasound ObstetGynecol*1995;6:3303.
 11. Malone FD, Ball RH, Nyberg DH. First-trimester septated cystic hygroma: prevalence, natural history and pediatric outcome. *ObstetGynecol* 2005;106.
 12. De Wit MC, Srebniak MI, Govaerts LCP, Van Opstal D, Galjaard RJH, Go ATJI. Additional value of prenatal genomic array testing in fetuses with isolated structural ultrasound abnormalities and a normal karyotype: a systematic review of the literature. *Ultrasound ObstetGynecol*2014;43:139– 146
